

# BEAUFORTIA

SERIES OF MISCELLANEOUS PUBLICATIONS

ZOOLOGICAL MUSEUM - AMSTERDAM

No. 79

Volume 7

July 21, 1958

## Tumours of reptiles 4.

### Multiple osteomas in the lizard *Lacerta viridis*\*)

by

A. STOLK

(Histological Laboratory, Free University, Amsterdam)

#### 1. INTRODUCTION

Whereas in fishes several osteomas (BELL, 1793; GERVAIS, 1875; BLAND-SUTTON, 1885; PLEHN, 1906; SCHROEDERS, 1908; FIEBIGER, 1909; WILLIAMSON, 1913; BEATTI, 1916; KAZAMA, 1924; SAGAWA, 1925; WILLIAMS, 1929; TAKAHASHI, 1929; THOMAS, 1932, 1933; LUCKÉ and SCHLUMBERGER, not published, see the publication of SCHLUMBERGER and LUCKÉ, 1948) and some osteosarcomas (WAHLGREN, 1873; MURRAY, 1909; WILLIAMS, 1929; THOMAS, 1932) have been described, in amphibians only one case of a doubtful osteogenic sarcoma (OHLMACHER, 1898) has been found and in reptiles one case of an osteoma (MOODIE, 1923).

Therefore, the multiple osteomas, which we were in a position to study in an adult female of the lizard *Lacerta viridis*, is probably the first case of this tumour found in a reptile. The tumour nodules presented themselves as rather regular nodules, varying in size, which were present in the tail and arose from the caudal vertebrae (figs. 1 and 2).

The tumours were fixed in Bouin d'Hollande fluid, decalcified with trichloroacetic acid and embedded in paraffin. The transversal serial sections (4--6 $\mu$ ) were stained with hematoxylin and eosin, hematoxylin and phloxin, and moreover according to the Van Gieson method and the azan method.

#### 2. DESCRIPTION

On the section the firm tumour nodules were grayish white in colour. Locally some strands of fibrous tissue were present. The nodules appeared without an exception to be connected with the caudal vertebrae.

The histological examination revealed that the nodules were composed of fibroblasts, osteoblasts, interlacing bundles of collagenous fibres and locally pieces of bone (figs. 3 and 4).

On the periphery of the nodules a layer of densely structured bone

\*) Received July 4, 1957.

was present. This layer appeared to be connected with the cortex of the vertebrae, which normally is only thin, but had strongly thickened. Locally the cortex had grown into a dense mass of bone in which actually no layer-like structure could be recognized any more.

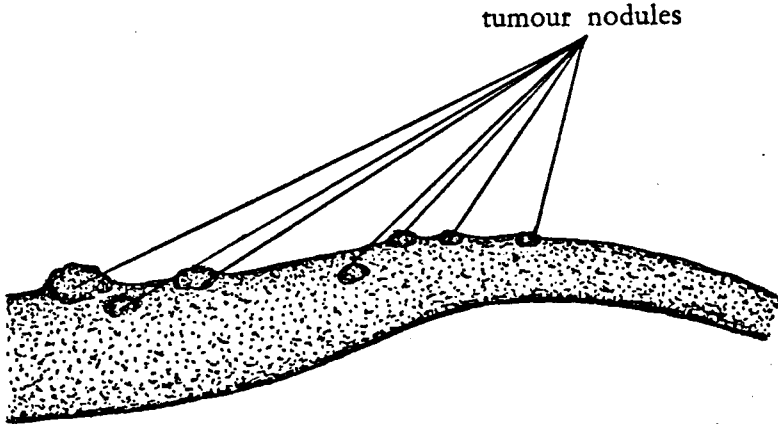


FIGURE 1. Multiple osteomas in an adult female of *Lacerta viridis*. Tail with tumour nodules, varying in size and arising from the caudal vertebrae.

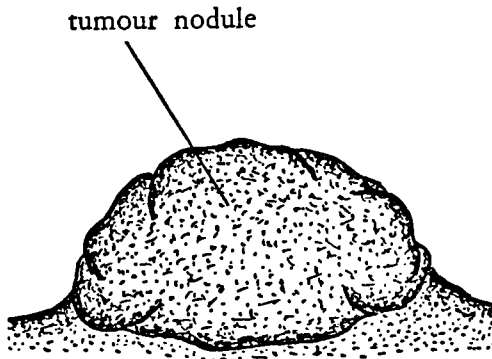


FIGURE 2. Multiple osteomas in an adult female of *Lacerta viridis*. Tumour nodule on the tail, starting from a caudal vertebra. Some times enlarged.

Centrally in the tumour nodules the structure was much looser. There the connective tissue was found with the fibroblasts and the osteoblasts and locally pieces of bone; in some areas also some more adipose tissue was present. On the strength of the looser structure of the tissue and the occurrence of the adipose tissue it must be assumed that this tissue originated from the bone marrow of the caudal vertebrae.

The fibroblasts had their normal appearance: elongated or star-shaped cells with large, oval nuclei with a delicate, sometimes slightly folded outline, dust-like chromatin particles and one or more large nucleoli.

Also the osteoblasts were normally structured and had a cytoplasm staining intensely with basic anilin dyes, suggesting the presence of

ribose nucleic acid, containing phosphatase and furnished with large nuclei with usually one fairly large nucleolus.

An important fact is that, as in the osteoma of the speckled trout *Salvelinus fontinalis* (THOMAS, 1932), some stages of transition were observed between typical fibroblasts and osteoblasts. Therefore we cannot but assume that in this case the osteoblasts were formed direct from the fibroblasts.

The pieces of bone were irregular and varied much in shape and size. In the bone no lines of fracture or indications thereof were visible.

The appearance of the tumour tissue was that of a fibrous connective tissue, in which an osseous metaplasia had occurred.

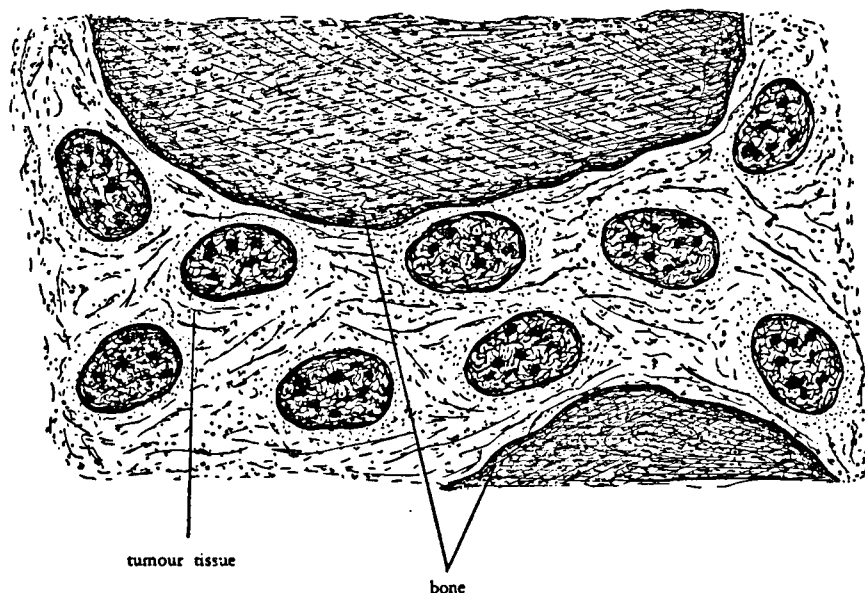


FIGURE 3. Multiple osteomas in an adult female of *Lacerta viridis*. Transversal section, low magnification. Tumour tissue, consisting of fibroblasts, osteoblasts and interlacing bundles of collagenous fibres with locally pieces of bone, varying in shape and size.

The vascularization of the tumour tissue was rather normal. Nowhere were the blood vessels situated closely together.

Dilated blood vessels, hemorrhages, necrotic areas, cysts and inflammatory processes were not observed.

The overlying skin was intact, and only showed a somewhat more irregular structure than in the normal case. Besides, in some regions the pigment had disappeared.

### 3. DISCUSSION

For comparison we give the literature data of osteomas and osteosarcomas, which were observed in lower vertebrates.

The osteomas described by BELL (1793) were present as nodules the size of hazel-nuts in the butterfly fish *Platax pinnatus*. The tumours were spongy and so soft that they could be easily cut with a knife; they

appeared to be filled with oil. This case is probably the first recorded account of a neoplasm in a fish.

The osteomas described by GERVAIS (1875) were found on the dorsal fin rays of a scabbard fish *Lepidopus species* and on the vertebral spines of the butterfly fish *Platax pinnatus*.

The osteomas described by BLAND-SUTTON (1885) were observed in a pike *Esox lucius* and in two specimens of the codfish *Gadus morhua*. The first tumour occurred on the dental plate and showed scattered through the tissue delicate spicules of bone. The second tumour had arisen from the maxilla and formed a heavy, disc-shaped, bony mass with a diameter of 2 inches and a thickness of half an inch. The third tumour originated from the vertebrae as an exostosis, measuring 1 cm in diameter. This tumour, which developed from the cartilaginous inter-vertebral discs must possibly be considered as an osteochondroma.

The osteoma described by PLEHN (1906) originated from the last vertebra of a pike *Esox lucius* as a hard tumour the size of a walnut.

The osteoma described by SCHROEDERS (1908) was observed as 15 multiple tumours on the vertebral spines of a flounder *Psetta maeotica*. The size of the tumours, which were attached to the bony rays, varied from a pin's head to that of a walnut. The firm tumours resembled normal bone and were covered by normal skin.

The osteoma described by FIEBIGER (1909) had arisen from the frontal bone of a 900-gram carp *Cyprinus carpio* and had the size of a child's fist. Much of the cranial cavity appeared to be obliterated by the tumour. Microscopically the tumour was composed of bone and cartilage. The arrangement resembled a normal enchondral bone formation.

The osteoma described by WILLIAMSON (1913) was present in a vertebral body of a codfish *Gadus morhua*.

The osteoma described by BEATTI (1916) consisted of multiple tumours of two vertebrae in a croaker *Pogonias chromis*. The author stated that he has observed several such lesions in this species.

The osteomas described by KAZAMA (1924) were present in 6 out of 500 specimens of the red tai *Pagrosomus major*. In one case the tumour presented itself as a nodular mass the size of a thumb-nail at the middle of the mandible. In the other cases the tumours were multiple and originated from the ventral spinous processes at the site of the union with the anal fin. According to the author the trauma may have evoked the lesions.

The osteoma described by SAGAWA (1925) was found in each of 2 specimens of the red tai *Pagrosomus major*. The tumour had the size of the tip of the little finger and grew on a spinous process of one of the caudal vertebrae.

The osteoma described by WILLIAMS (1929) had arisen as a protuberance, measuring 5 × 2 cm, from the anterior portion of the left premaxilla of a codfish *Gadus morhua*. The tumour consisted of typical bone with Haversian canals and vascular spaces and was covered by an intact overlying skin.

The osteomas described by TAKAHASHI (1929) were present in the coalfish *Theragra chalcogramma*, the flatfish *Paralichthodes olivaceus*, the red tai *Pagrosomus major* and the rock fish *Sebastes inermis*. The osteomas of the coalfish *Theragra chalcogramma* were observed in 8

specimens. In 6 animals the tumours, some of which were as large as a small hen's egg, were present in the spines of the dorsal fin. One of these tumours was certainly an osteoma. In the remaining 2 cases symmetrical osteomas the size of a thumb-nail were observed near the posterior margin of the operculum. These cases, with the exception of the one of osteoma, must possibly be considered as osteochondromas.

The osteoma of the flatfish *Paralichthodes olivaceus* was a firm, spherical, bony tumour, which was situated on the spinous process of the third lumbar vertebra. In consequence of the pressure which the tumour had produced a local atrophy of the adjacent vertebral body had developed.

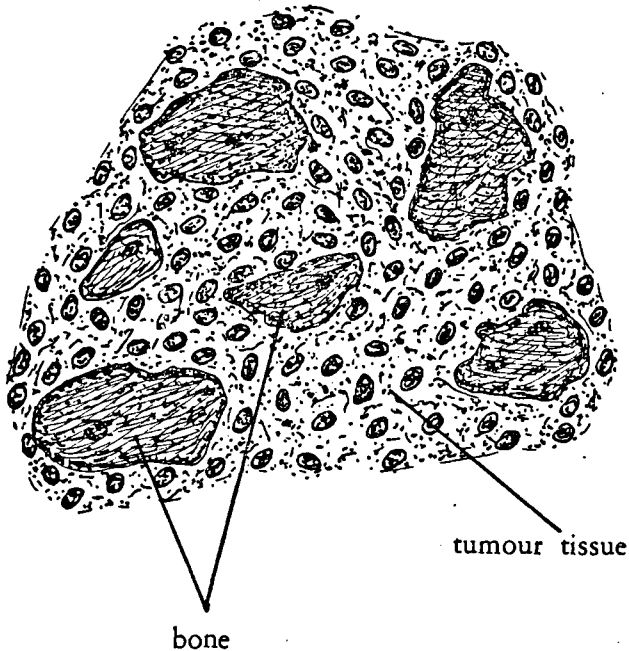


FIGURE 4. Multiple osteomas in an adult female of *Lacerta viridis*. Transversal section, higher magnification. Tumour tissue, consisting of fibroblasts, osteoblasts interlacing bundles of collagenous fibres with locally pieces of bone,

The osteomas of the red tai *Pagrosomus major* were found in 102 specimens. The tumours varied from the size of a pea to that of a large bean. Some tumours were as large as a walnut. In 28 cases the tumour was single, in 64 cases 2 tumours were present, in 17 cases 3 tumours, in 10 cases 4 or more tumours. In several of the very small tumours a line of fracture was visible. The author comes to the conclusion that the ossification of an excess callus formation is the initial step in the formation of these tumours.

The osteomas of the rock fish *Sebastes inermis* were present in the dorsal fin.

Three specimens of *Pagrosomus major* were chosen by LUCKÉ and SCHLUMBERGER (not published, cited by SCHLUMBERGER and LUCKÉ,

1948) at random from the collection at the National Museum in Washington. One specimen bore tumours which were identical with those described by TAKAHASHI. In view of its importance we quote the report of their examination :

„Careful inspection of the roentgenograms and histologic sections failed to reveal convincing evidence of previous fracture. The cortex, which is very thin in the normal spinous process, was greatly thickened. As the growths increased in size the cancellous bone became more prominent until only a thin cortical layer of dense bone remained. The marrow spaces were filled with well vascularized adipose tissue ; hematopoiesis does not occur in the bone marrow of fishes, hence its absence in the osteomas could be anticipated. In considering the etiology of these tumours the following characteristics must be taken into account : their frequent occurrence in a particular species, the predominance of the tumors in the spines of the sixth to eighth caudal vertebrae and the predilection of the tumors for fishes over 20 cm. in length. A traumatic origin, as suggested by Takahashi and Kazama, does not adequately explain all these features of the neoplasm. An elucidation of the problem must await study of the tumor in the living animal.

Chabanaud has described a localized fusiform hypertrophy characteristic of certain spines of the dorsal fin in several species of fishes — *Corvina clavigera*, *C. nigrita*, and *Sciaenoides perarmatus*. The enlargement of the spines was absent in very young fish, but became manifest with increasing age. The author concluded that these hypertrophies were not accidental, but might be "integrated with the metabolism of the species".

Dr. L. P. Schultz, ichthyologist of the National Museum in Washington, called our attention to similar changes in the angelfish *Chaetodipterus faber*. In old individuals of this species a localized hypertrophy of the distal portion of the first interhaemal spine tends to develop. The enlargement may become massive, in some instances measuring as much as  $4.5 \times 3 \times 2.5$  cm. Histologic examination revealed that the tumor consists of cancellous bone and concentrically arranged bands of more condensed osseous tissue. A similar laminated structure is found in the otoliths of fishes, where it is believed to result from periodic (seasonal) fluctuations in the rate of growth. The adipose tissue that had filled the marrow cavity was still recognizable in some regions, but elsewhere had almost disappeared. This overgrowth of bone probably represents a hyperostosis, rather than an osteoma."

The osteomas described by THOMAS (1932 and 1933) occurred in the speckled trout *Salvelinus fontinalis* and the cat shark *Scylliorhinus canicula*. The speckled trout was a 5-year old fish, which possessed many firm, white tumour nodules, which were located at the base of the rays supporting the ventral portion of the caudal fin and measured between 3 and 7 mm in diameter. The covering skin appeared to be normal with the exception of an absence of pigment granules in some regions. The histological examination revealed stages of transition between fibroblasts and osteoblasts. The general appearance of the tumour tissue was that of a connective tissue, in which an osseous metaplasia had taken place.

In the cat shark the firm, white tumour, measuring  $4 \times 6$  mm, was situated on the back, immediately anterior to the dorsal fin. Much of the tumour tissue consisted of osteoid tissue. Yet in some regions osteoblasts were found and true bone was formed.

The osteomas described by LUCKÉ and SCHLUMBERGER (not published, cited by SCHLUMBERGER and LUCKÉ, 1948) were observed in the angelfish *Chaetodipterus faber* and the file fish *Alutera schoepfi*.

In 4 specimens of the angelfish several of the spines bear symmetrical hyperostoses. One specimen bore an irregular overgrowth, which may be classified as an osteoma on one of the bones of the shoulder girdle, namely on the cleithrum.

In the file fish the osteoma was present as a large tumour, originating from the first interneural spine.

The osteosarcoma described by WAHLGREN (1873) was observed as a nodular growth, measuring  $8 \times 5.5$  cm, on the anal fin of a 3-foot pike *Esox lucius*. On the section the tumour, which was covered by an intact skin, had the appearance of bacon and was traversed by irregular osseous trabeculae. Histologically the soft tumour tissue was composed of small, irregular cells furnished with one or more nuclei. The tumour cells were surrounded by a partially hyalinized connective tissue.

The osteosarcoma described by MURRAY (1908) was a hemispherical osseous tumour with a diameter of 2 cm in the subcutaneous connective tissue of the operculum of a codfish species not given. Microscopically it consisted of irregular rounded masses of osseous tissue, which were separated by strand of spindle-shaped cells. In the tumour tissue numerous thin-walled capillaries were present, which were irregularly arranged.

The osteosarcoma described by THOMAS (1932) was localized immediately behind the left pectoral fin of a young codfish *Gadus morhua*. The tumour bulged into the peritoneal cavity, infiltrated the adjacent trunk musculature and measured  $4.5 \times 2.0 \times 1.5$  cm. The cut surface of the soft tumour was gray-white and marked by many punctate hemorrhages. Among the pleomorphic cells plaques of osteoid tissue and multinucleated giant cells were observed.

The osteogenic sarcoma described by OHLMACHER (1898) was present in the left femur of a frog *Rana virescens* as a spindle-shaped swelling, which occupied the entire length of the femur and had reached a maximum diameter of 8 mm. The periosteum appeared to be intact. Microscopically the tumour was composed of trabeculae of bone and cartilage, which were surrounded by large spaces. In the latter rapidly proliferating mononuclear cells were found, which appeared to be derivatives of the bone marrow. According to the author the lesion was a medullary osteosarcoma. SCHLUMBERGER and LUCKÉ (1948) would seem right in their opinion that the description is more suggestive of callus formation after fracture. MURRAY (1908) described a similar lesion in a frog and came to the conclusion that it probably represented a callus formation rather than a bone tumour.

The osteoma described by MOODIE (1923) was situated in the third dorsal vertebra of a mosasaur, an aquatic reptile with large dimensions, which lived during the latter part of the Cretaceous.

In this connection mention may also be made of the tumour-like lesions which were observed in the caudal vertebrae of three dinosaurs, though they are in general not considered as true tumours. These lesions have been interpreted as an excess callus formation following a fracture, as osteomyelitis and a hemangioma. MOODIE (1923) discussed one of the lesions in detail and cited two other cases reported by HATCHER (1901) and by HOLLAND (1906). This author comes to the conclusion that they were hemangiomas. According to SCHLUMBERGER and LUCKÉ (1948) the description of HATCHER and HOLLAND strongly suggest, that the lesions were benign overgrowths following fracture, rather than neoplasms.

When comparing the osteomas of *Lacerta viridis* with the above-mentioned tumours we come to the conclusion that the agreement is

strongest with the osteomas in the speckled trout *Salvelinus fontinalis* (THOMAS, 1932). As the most important points of agreement may be mentioned :

1. the stages of transition between the fibroblasts and the osteoblasts ;
2. the general appearance of osseous metaplasia ;
3. the intact overlying skin ;
4. the absence of pigment in some regions of the skin.

As no lines of fracture or indications thereof were observed, we cannot explain the origin of these *Lacerta* osteomas by means of a trauma, as suggested by TAKAHASHI (1929). With LUCKÉ (not published, cited by SCHLUMBERGER and LUCKÉ (1948)) we therefore deny this traumatic genesis.

#### 4. SUMMARY

Description of multiple osteomas in an adult female of the lizard *Lacerta viridis*. The tumour nodules were present on the tail, arose from the caudal vertebrae and were composed of a tumour tissue with fibroblasts, osteoblasts, interlacing bundles of collagenous fibres and locally pieces of bone. These tumours were probably not of traumatic origin.

#### 5. REFERENCES

- BEATTI, M.  
1916 Geschwülste bei Tieren. Zeitschr. f. Krebsforsch., 15 : 452.
- BELL, W.  
1793 Description of a species of *Chaetodon*. Phil. Trans. Roy. Soc. London, 7.
- BLAND-SUTTON, J.  
1885 Tumours in animals. J. Anat. and Physiol., 19 : 415.
- CHABANAUD, P.  
1926 Fréquence, symétrie et constance spécifique d'hyperostoses externes chez divers poissons de la famille des Sciaenides. Compt. rend. Séances l'Acad. Sci., 182 : 1647.
- FIEBIGER, J.  
1909 Ein Osteochondroma bei einem Karpfen. Zeitschr. f. Krebsforschung, 7 : 371.
- GERVAIS, P.  
1875 De l'hyperostose chez l'homme et chez les animaux. J. de Zool., 4 : 272, 445.
- HATCHER, J. B.  
1901 *Diplodocus*, Marsh, its osteology, taxonomy, and probable habits with a restoration of the skeleton. Mem. Carnegie Mus., Pittsburgh, 1 : 36.
- HOLLAND, W. J.  
1906 The osteology of *Diplodocus*, Marsh. Mem. Carnegie Mus., Pittsburgh 2 : 255.
- KAZAMA, Y.  
1924 Einige Geschwülste bei Fischen (*Pagrus major* et *Paralichthys olivaceus*) Gann, 18 : 35.
- LUCKÉ, B. and H. G. SCHLUMBERGER  
Not published. Cited by SCHLUMBERGER and LUCKÉ.
- MOODIE, R. L.  
1923 Paleopathology. University of Illinois Press, Chicago.
- MURRAY, J. A.  
1908 The Zoological distribution of cancer. Sci. Repts. Imp. Cancer Res. Fund., 3 : 41.
- OHLMACHER, H. P.  
1898 Several examples illustrating the comparative pathology of tumors. Bull. Ohio Hosp. Epilep., 1 : 223.
- PLEHN, M.  
1906 Über Geschwülste bei Kaltblütern. Zeitschr. f. Krebsforsch., 4 : 525.
- SAGAWA, E.  
1925 Zur Kenntnis der Fischgeschwülste. Gann, 19 : 14.



- SCHLIMBERGER, H. G. and B. LUCKÉ  
 1948 Tumors of fishes, amphibians, and reptiles. *Cancer Research*, 8 : 657.
- SCHROEDERS, V. D.  
 1908 Tumors of fishes. Thesis (Russian). (Translation in Army Med. Library, Washington, D.C.). St. Petersburg.
- TAKAHASHI, K.  
 1929 Studie über die Fischgeschwülste. *Zeitschr. f. Krebsforsch.*, 29 : 1.
- THOMAS, L.  
 1931 Adénome kystique de l'intestin moyen chez une truite pourpre. *Bull. Assoc. franç. p. l'étude Cancer*, 20 : 575.
- THOMAS, L.  
 1932 Deux cas de tumeurs osseuses chez des Téléostéens. *Assoc. franç. p. l'étude Cancer* 21 : 280.
- THOMAS, L.  
 1933 Sur deux cas de tumeurs tégumentaires chez la rousette. *Assoc. franç. p. l'étude Cancer* 22 : 306.
- WAHLGREN, F.  
 1873 Beiträge zur Pathologie der wilden Tiere. *Deutsch. Zeitschr. f. Tiermed. u. Vergl. Path.* 2 : 232.  
 Translated from the Swedish original in *Oefoers af Wet. Akad. Forhandl.* (1873).
- WILLIAMS, G.  
 1929 Tumorous growths in fish. *Proc. and Trans. Liverpool Biol. Soc.* 43 : 120.
- WILLIAMSON, H. C. Report diseases and abnormalities of fishes. *Ann. Rept. Fish. Bd.*, 1909-13 Scotland, Pt. 3 : 56. Cited by THOMAS (1931).